



## PATIENT

Zeus Nisexic

## SPECIES

Canine

## BREED

Labrador Retriever

## SEX

MN

## AGE

10 y

## WEIGHT

69 lb

## PRESENTING CLINICAL SIGNS

Episodes of collapse. Limp, blue, gasping for air, weakness. Arrhythmia. No murmur.

## ECHOCARDIOGRAPHIC FINDINGS

2D, M-mode, and Doppler study.

Left atrial size is normal. The mitral valve appears normal, though trace mitral regurgitation is present. Left ventricular dimensions are normal. Left ventricular systolic function is normal. The aorta and aortic valve are normal. Right atrial and right ventricular dimensions are normal. The tricuspid valve leaflets are mildly thickened, and a mild jet of tricuspid regurgitation is present. TR velocity does not suggest the presence of pulmonary hypertension. The pulmonary artery and pulmonic valve appear normal, though trace pulmonic insufficiency is present. No shunting lesions are visualized. No pericardial effusion or cardiac masses are seen.

LA - 45.3 mm

LVIDd - 45.0 mm

LVIDs - 32.9 mm

FS - 26.9%

RA - 31.6 mm

LVOT - 1.01 m/s

RVOT - 0.75 m/s

TR - 2.02 m/s

## INTERPRETED BY

Keith Blass, DVM, MS,  
DACVIM (Cardiology)

## ASSESSMENT/RECOMMENDATIONS

Degenerative tricuspid valve disease - stage B1

This examination demonstrates mild regurgitation of blood across Zeus's tricuspid valve resulting from degenerative valve disease. The hemodynamic effects of the regurgitation also appear to be mild, as Zeus does not have secondary dilation of either of his right heart chambers. As such, Zeus's current risk for the development of right-sided congestive heart failure appears to be low.

No reason for Zeus's episodes of collapse, other presenting clinical signs, or arrhythmia is appreciated in this exam.

An ECG is recommended to further evaluate Zeus's arrhythmia. Thoracic radiographs may be warranted to evaluate Zeus's gasping for air.

No therapy is recommended based on Zeus's echocardiogram.

A recheck echocardiogram is recommended in 6-9 months to monitor for disease progression.

## DATE

2/9/26

## IMAGING PERFORMED BY

Meghan Morse, LVT,  
CVT

## HOSPITAL NAME

Farview AC

## REFERRING VET

Dr. Mosaad

## INVOICE



#### PATIENT

Zeus Nisexic

#### SPECIES

Canine

#### BREED

Labrador Retriever

#### SEX

MN

#### AGE

10 y

#### WEIGHT

69 lb

#### INTERPRETED BY

Keith Blass, DVM, MS,  
DACVIM (Cardiology)

#### IMAGING PERFORMED BY

Meghan Morse, LVT,  
CVT

#### HOSPITAL NAME

Farview AC

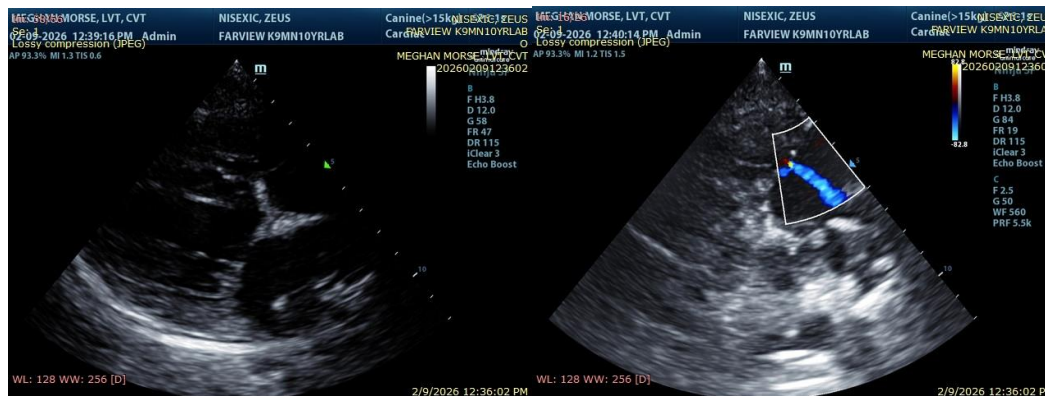
#### REFERRING VET

Dr. Mosaad

#### INVOICE

#### DATE

2/9/26



The information and recommendations provided are based on the images presented by the referring veterinarian/sonographer. No evaluation can be communicated regarding pathology that was not visible in the image/video clips provided.

Thank you for this referral. If the clinical or image interpretation does not parallel your findings or if I can be of any further assistance please contact me.

Keith Blass, DVM, MS, DACVIM (Cardiology)

[info@SonoPath.com](mailto:info@SonoPath.com)